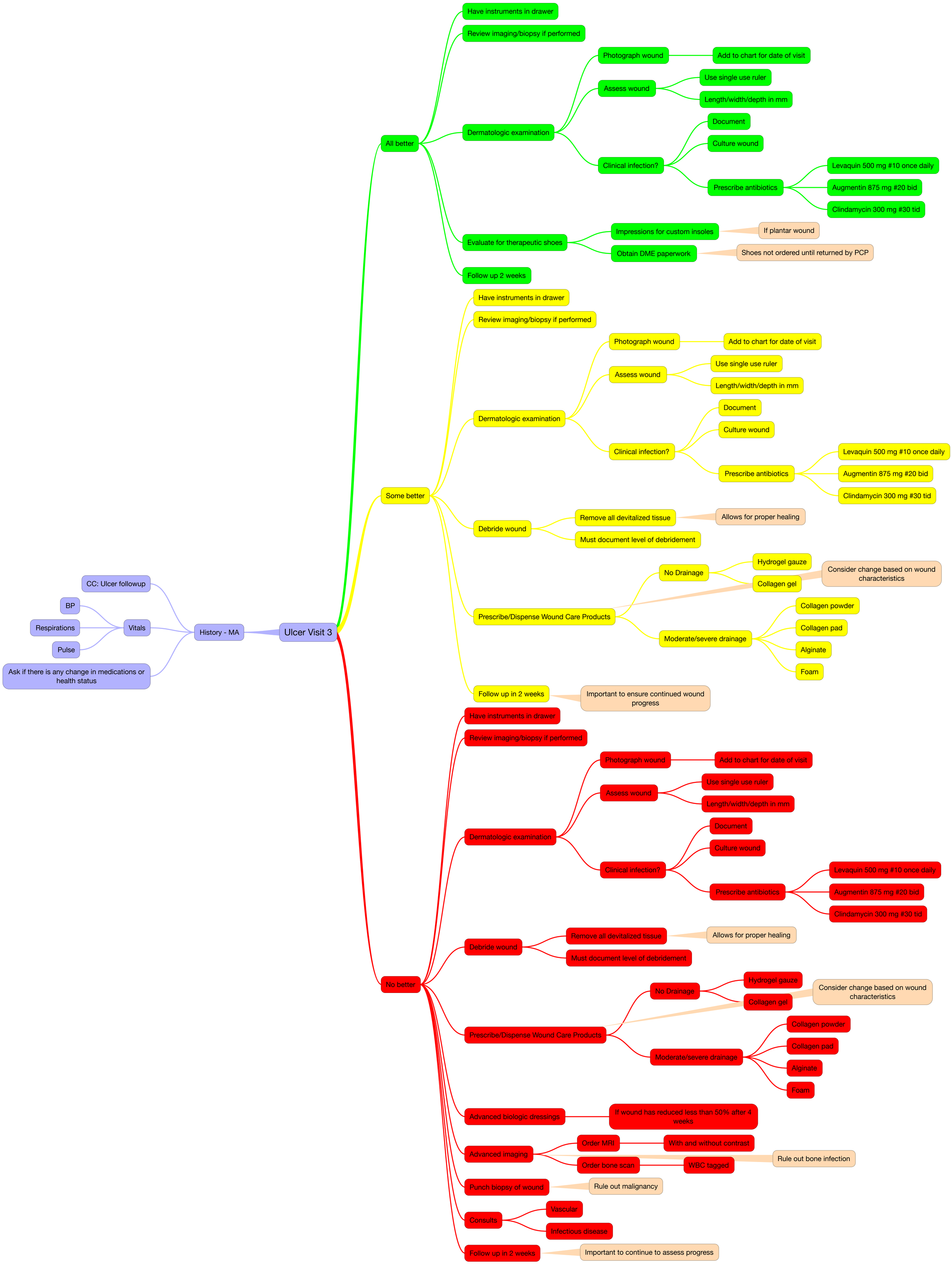
Ulcer Visit 3
History - MA
CC: Ulcer followup
Vitals
BP
Respirations
Pulse
Ask if there is any change in medications or health status
All better
Have instruments in drawer
Review imaging/biopsy if performed
Dermatologic examination
Photograph wound
Add to chart for date of visit
Assess wound
Use single use ruler
Length/width/depth in mm
Clinical infection?
Document
Culture wound
Prescribe antibiotics
Levaquin 500 mg #10 once daily
Augmentin 875 mg #20 bid
Clindamycin 300 mg #30 tid
Evaluate for therapeutic shoes
Impressions for custom insoles
If plantar wound
Obtain DME paperwork
Shoes not ordered until returned by PCP
Follow up 2 weeks
Some better
Have instruments in drawer
Review imaging/biopsy if performed
Dermatologic examination
Photograph wound
Add to chart for date of visit
Assess wound
Use single use ruler
Length/width/depth in mm
Clinical infection?
Document
Culture wound
Prescribe antibiotics
Levaquin 500 mg #10 once daily
Augmentin 875 mg #20 bid
Clindamycin 300 mg #30 tid
Debride wound
Remove all devitalized tissue
Allows for proper healing
Must document level of debridement
Prescribe/Dispense Wound Care Products
No Drainage
Hydrogel gauze
Collagen gel
Consider change based on wound characteristics
Moderate/severe drainage
Collagen powder
Collagen pad
Alginate
Foam
Follow up in 2 weeks
Important to ensure continued wound progress
No better
Have instruments in drawer
Review imaging/biopsy if performed
Dermatologic examination
Photograph wound
Add to chart for date of visit
Assess wound
Use single use ruler
Length/width/depth in mm
Clinical infection?
Document
Culture wound
Prescribe antibiotics
Levaquin 500 mg #10 once daily
Augmentin 875 mg #20 bid
Clindamycin 300 mg #30 tid
Debride wound
Remove all devitalized tissue
Allows for proper healing
Must document level of debridement
Prescribe/Dispense Wound Care Products
No Drainage
Hydrogel gauze
Collagen gel
Consider change based on wound characteristics
Moderate/severe drainage
Collagen powder
Collagen pad
Alginate
Foam
Advanced biologic dressings
If wound has reduced less than 50% after 4 weeks
Advanced imaging
Order MRI
With and without contrast
Order bone scan
WBC tagged
Rule out bone infection
Punch biopsy of wound
Rule out malignancy
Consults
Vascular
Infectious disease
Follow up in 2 weeks
Important to continue to assess progress